



AORTIC DISSECTION (TYPE A) AND AORTIC ANEURYSM

Khurram Shahzad, Najeeb Ullah, Tahir Naveed

34 years old male ex-smoker with family history of ischemic heart disease presented with sudden onset of chest discomfort and shortness of breath with mild ST-T changes in emergency department. His echocardiography showed type A Aortic dissection with severe aortic regurgitation, dilated LV and moderate to fair LV function .

He was immediately referred for the CT angiogram(MDCT) that showed annulaortic aneurysm and a dissection flap starting from aortic root near RCA ostium and extending into ascending aorta(99mm),aortic arch, descending thoracic aorta and abdominal aorta upto the level of bifurcation. The dissection is also extending into brachiocephalic trunk, right common carotid and right subclavein artery.

(J Cardiovasc Dis 2012;10(2):63-64)

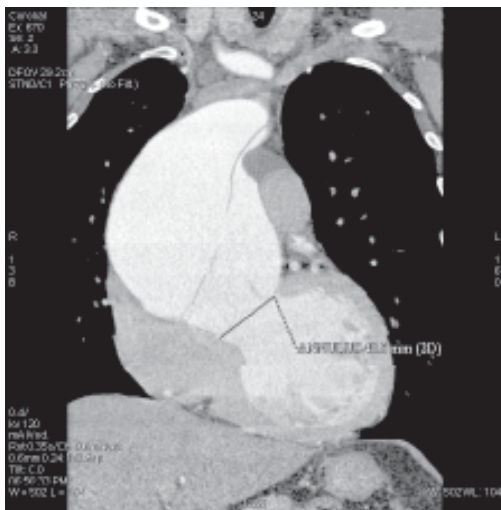


Figure 1: showing the dissection flap in the aortic root and dilated annulus

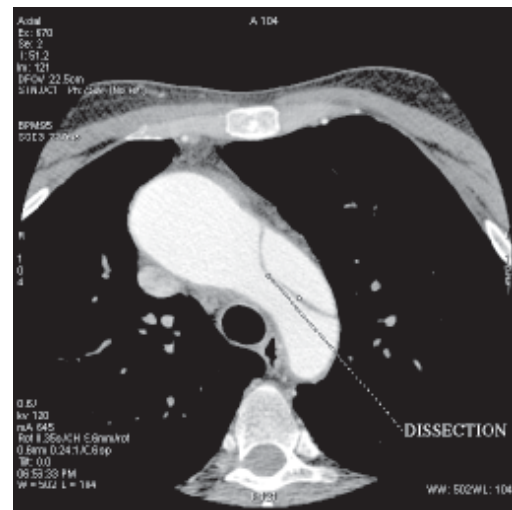


Figure 3: dissection involving the arch of aorta

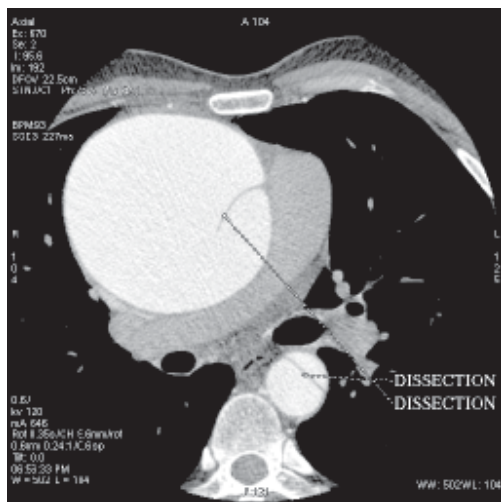


Figure 2: Dissection flap in the ascending and descending aorta.

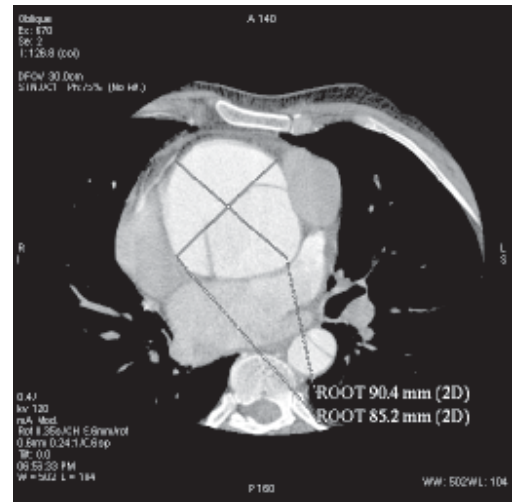


Figure 4: dilated aortic root

